

See discussions, stats, and author profiles for this publication at: <https://www.researchgate.net/publication/260134855>

SPERMATOGENIC ACIVITY OF SIDDHA DRUG – RESEARCH

Article · April 2013

CITATIONS

0

READS

60

1 author:



Thillai Vanan

Govt Hospital,, TamilNadu Medical Service

18 PUBLICATIONS 3 CITATIONS

SEE PROFILE



SPERMATOGENIC ACTIVITY OF ISAPPUKOL CHOORANAM (SIDDHA DRUG) AGAINST TCDD INDUCED OLIGOSPERMIC RATS



P. PARTHIBAN¹, K. KANAGAVALLI²,
J. ANBU⁴, S. THILLAIVANAN⁵, P. SATHIYARAJESWARAN³



1. Prof & HOD, PG Maruthuvam Dept, GSMC, Chennai.
2. Prof & HOD, UG Maruthuvam Dept., GSMC, Chennai.
3. Research officer, Siddha Central Research Institute, Chennai.
4. Prof & HOD Pharmacology & Toxicology, Vels University, Chennai.
5. PG Scholar, Maruthuvam branch, GSMC, Chennai.

Accepted Date:

13/04/2013

Publish Date:

27/04/2013

Keywords

Isappukol chooranam,
Oligospermia,
Male Infertility,
Spermatogenic activity,
TCDD.

Corresponding Author

Mr. S. Thillaivanan

Abstract

Infertility is one of the most extremely tragic of all marital problems. Despite recent advances in the treatment of male infertility, the problem has not been satisfactorily tackled. The male infertility is mainly due to an inadequate number of spermatozoa in the semen, the failure of the spermatozoa to move with sufficient vigor towards their goal. Aim of the study is to investigate the safety and efficacy of Isappukol chooranam(IC) (siddha drug). IC was evaluated for spermatogenic activity against TCDD (2,3,7,8-TETRACHLORODIBENZO-P-DIOXIN) induced oligospermic rats, administrated at the doses of 50 mg and 100 mg /kg body weight per day for 14 and 28 days. Body and reproductive organ weight, such as testis, cauda epididymidis, seminal vesicle and prostate gland, hematological, biochemical parameters and level of testosterone were investigated. The Isappukol chooranam induce a significant increase in the weight of reproductive organs as compared to control animals (P<0.01). The sperm count, motility and viability in cauda Epididymides and testicular ducts were significantly increased (P<0.05). Epididymides showed elevated number of spermatozoa. Lumen of vas deferentia was full of sperms. The secretary activities of seminal vesicle and ventricular prostate were also increased. A significant increase in spermatogenesis activity was observed in seminiferous tubule. Significant (P>0.01) increase in testosterone level of the treated group compared to control. The overall findings may be helpful to the population not only to treat Male Infertility but also to maintain normal sexual life. It is concluded that the Isappukol chooranam have increased spermatogenesis of adult male rats and it can be used more effectively in the treatment of Oligospermia and male infertility.

INTRODUCTION

Infertility is the failure of a couple to conceive a pregnancy after trying to do so for at least one full year. Approximately 20% of couples struggle with infertility at any given time. Infertility has increased as a problem over the last 30 years^[1]. Infertility accounts for female, male and both is 40%, 40%, 20% respectively. Male reproductive health has social and psychological impact on normal life^[2]. Male infertility is commonly due to deficiencies in the semen and semen quality is used as a surrogate measure of male fecundity^[3]. Male reproductive medicine and surgery remains one of the most actively evolving areas in urology, with a variety of therapeutic modalities under investigation^[4]. Conventional treatment for infertility usually involves invasive and, expensive procedures. There are many alternative treatments available that can increase the chance of conception^[5]. Though, there are various treatments for infertility, many diagnostic methods are quite embracing to the patients, which again affect the sexual activity. Scientists have devised different ways of alienating the problem and one of the easy and cheapest options is herbal

medicines. Herbs have been in use since long time to treat various diseases^[6]. The present study was conducted to evaluate the possibility of using Isappukol chooranam as a therapeutic agent to treat Spermatogenic disorders in the animal models. The interventional drug Isappukol chooranam has been quoted by Koshayi Anuboga Vaithya Brama Ragasiyam, whose efficacy is not proved. The drug is holding ThathuViruthi property which is analogues with Spermatogenic activity^[7]. The drug is chosen for the treatment of Aanmaladu (Male Infertility) quoted by Yugi Muni^[8].

MATERIALS AND METHODS

Preparation of the Isappukol chooranam:

2 part of, seed of Isappukol (Plantago ovata)^[9], 1 part of Jadhikkai (Myristica fragrans)^[9], 2 part of seed of Neermulli (Hygrophila auriculata)^[9], and 6 part of karkandu (Rock candy) were dried and powdered & mixed well^[10].

Ingredients of the Isappukol chooranam:

1. Isappukol vithai 2. Jadhikkai 3. Neermulli vithai 4. Karkandu



Aim

Aim of the study is to evaluate the safety and efficacy of the siddha drug 'Isappukol chooranam'.

Chemicals

The 2, 3, 7, 8-Tetrachloro dibenzo-p-dioxin and necessary chemicals and reagents were obtained from Sigma chemicals. All other solvents and Analytical Kits were of analytical grade and obtained from qualigen fine chemicals and Artek laboratories.

Animals

Adults male rats weighing between 152-167g and albino mice weighing between 25-34g (For acute toxicity study) were maintained in a well ventilated animal house under standard condition of humidity, temperature and a constant 12 hour light:12 hour dark lighting schedule. The animals were housed in clear

polypropylene cages. The animals were maintained with standard pellet feed (SaiDurga Feeds and Foods, Bangalore, India) and water ad libitum. The health, normal behavior and reproductive status of the animals were assessed and only healthy animals were selected for the experiment. All experimental procedures described were reviewed and approved by the Institutional Animal Ethical Committee of Vel's College of Pharmacy, Chennai-117 on 11.08.2012 bearing no. (XIII/VELS/PCOL/27/2000/CPCSEA/IAEC/08.08.2012).

Drug Stock solution

The powdered form of Isappukol chooranam was mixed uniformly in 2% CMC and made into uniform suspension to achieve 200mg/ml as main stock solution and used in this study.

Acute oral toxicity study

The acute oral toxicity study was carried out as per the guidelines set by Organization for Economic Co-operation and Development (OECD), revised draft guidelines 425 (Up and Down method) received from Committee for the Purpose of Control and Supervision of Experiments on Animals

(CPCSEA). The test substances were administered in a single dose using a gastric intubation tube after fasting for 3 to 4 hours^[11].

Since there was no information on the substance to be tested, starting dose was 2000 mg/kg body weight up to 5000 mg/kg body weight. Animals were observed initially after dosing at least once during the first 30 min, periodically during the first 24 h. In all cases death was observed within first 24h. Attention was also given to observations of behavioral changes and toxic symptoms like tremors, dyspnoea, writhing and convulsions etc.

Evaluation of Spermatogenic activity

Animal grouping and Treatment

Twenty four adult male rats were randomly divided into four groups of six animals each. Group 1 (control) was administered with the vehicle (2% CMC suspension) while groups 2 and 3 were given suspension of Isappukol Chooranam at 50mg/kg and 100mg/kg. One rat was sacrificed to ensure the oligospermic induction at the beginning of the experiment ie after one week of TCDD injection. Two rats from each treatment group were randomly sacrificed

after 14 days of Isappukol Chooranam administration while the remaining rats treatment were continued up to 28 days. Treatment was done daily using oral dosing needle and twenty four hours after the last dose, blood was collected and the animals were sacrificed. All procedures regarding handling of the test animals were in accordance with the existing CPCSEA and IAEC guidelines.

Induction of Oligospermia by TCDD in rats

Initially, rats were injected with 40µg TCDD/kg i.p. At one week after TCDD exposure, a rat from each group was selected and tested for induction of Oligospermia and after ensuring the oligospermic conditions the study was preceded further^[12].

Blood sample and organ collection

After the last dosing of Isappukol chooranam, all the animals were sacrificed by employing euthenesia procedure and the testes, epididymis, vas deferens, seminal vesicles and ventral prostates were identified, dissected out, blotted free of blood and cleared of connective tissue or fat. The organs were weighed immediately using a electronic digital balance. Blood

samples were collected by retro-orbital puncture into anticoagulant pre-coated and also in plain sterile eppendorff tubes and allowed to clot at room temperature. Serum samples were separated by centrifugation at 3000 rpm for 10 min and stored at -20°C until testosterone assay. Anticoagulant added blood samples were used for the studying hematological parameters.

Sperm collection and Measurement of sperm parameters

The rats were anaesthetized with anesthetic ether and sacrificed after the last day of administration and weighed for the essential reproductive organs, such as testis, caudal epididymis, seminal vesicle and prostate glands. A scrotal incision was made to exteriorize the testis and epididymis. The epididymis were carefully dissected out of the testes and blotted free of blood. To prepare sperm suspension, epididymal sperm were obtained by mincing cauda epididymidis of each rat in pre-warmed beaker containing 2 ml of physiological saline (maintained at 37°C). Several incisions were made on it to allow sperm swim out.

Sperm characteristics were determined according to the standard protocols derived by the previous investigators in this research area. Sperm motility was also assessed immediately by counting both motile and immotile spermatozoa per unit area at the 40x magnification. Sperm count was done using the improved Neubauer's haemocytometer under the light microscope at 100x magnification. The count was expressed as million/ml of suspension. Sperm viability was assessed using eosin-nigrosin test. The percentages of unstained (alive) and stained (dead) spermatozoa were calculated by counting 100 spermatozoa randomly per sample. Morphological appearance of normal and abnormal spermatozoa was determined by examining stained smears under the oil immersion (100 x) and their percentages were calculated.

Testosterone Assay

Blood samples were spun at 2500rpm for 10 minutes in a table top centrifuge. The serum samples obtained were analyzed to determine the concentration of testosterone. The analysis was carried via

the tube-based enzyme immunoassay method as described in the kit^[13].

Collection of tissues and histological analysis

The testes were collected and immediately fixed in Bouins fluid for 6 h and transferred to 70% alcohol for histological processing^[14]. And following fixation of the testes from both control and test animals, tissue sections were processed by dehydration in 95% and absolute alcohol, cleared in xylene and embedded in pure clean molten paraffin wax from which blocks of tissues were made for sectioning. Ribbon slices of about 5.0 μ m in thickness were made with the aid of a microtome and the sections picked with slides which were dried in oven. The slices were then stained with Haemotoxylin and Eosin, and then mounted using DPX onto a light microscope (magnification 40x) for histopathological and morphological changes^[15]. The changes observed were recorded and photomicrographs of the most prominent pathological alterations.

Statistical Analysis

The results were analyzed by one-way analysis of variance using INSTAT version 3

for Windows. Significant differences within group variables were determined by Tukey's multiple comparison tests. Results were considered significant at 5% level of probability ($P < 0.05$). The data were presented as mean \pm SEM.

RESULTS AND DISCUSSION

In the toxicity study, No specific signs of toxicity were seen in any of the animals except mild diarrhea. Hence as per the guideline the one tenth & fifth of maximum tolerable doses were selected for further pharmacological study. However, most of the animals exhibited calmness; improve appetite for food and water and general well-being during the administration of Isappukol chooranam upto 500 and 1000mg/kg dose orally.

Male fertility requires the production by the testis of large numbers of normal spermatozoa through a complex process known as spermatogenesis. This process can be subdivided into three major steps: (i) the multiplication of spermatogonia by the process of mitosis; (ii) meiosis, which reduces the chromosome number from diploid to haploid and commences with the entry of type B spermatogonia into the

prophase of the first meiotic division. These cells, now called primary spermatocytes, divide to form secondary spermatocytes, and then divide again to form round spermatids; (iii) the successful transformation of the round spermatid into the complex structure of the spermatozoon, this phase is being called spermiogenesis [16].

Each of these steps represents a key element in the Spermatogenic process. Defects which occur in any of them can result in the failure of the entire process and lead to the production of defective spermatozoa and reduction or absence of sperm production. It is therefore essential that our understanding of these processes is expanded to provide information concerning the regulatory mechanisms. Oral administration of the Isappukol chooranam for four weeks showed that the body weights increased significantly ($P < 0.05$) from 164.20 ± 2.06 and 188.60 ± 1.33 to 168.36 ± 1.86 and 184.52 ± 2.64 , respectively. Significant increases ($P < 0.01$) in weights of testes, epididymis, ventral prostate, seminal vesicles and vas deferens were observed in the treated groups compared with the control.

The sperm count was significantly ($P < 0.01$) higher in test drug Isappukol chooranam groups than the control in a dose related manner. In addition, the sperm motility and morphology of the test groups were also significantly ($P < 0.01$) higher than the control. Furthermore, the percentages of abnormal sperm cells in treatment groups were reduced compared to the oligospermic control but it was statistically not significant. Similarly, Significant ($P > 0.01$) increase in testosterone level of the treated group compared to control. Moreover, the low dose testosterone level was also significantly different from the control. TCDD and its related congeners have been shown to act as developmental and reproductive toxicants, which reduce testicular and accessory sex organ weights, alter testicular morphology, and decrease sperm production. In the control group, histopathologic examinations of seminiferous tubules showed the usual arrangement of Leydig's cell, Sertoli cells, and intracellular spaces.

However, in TCDD-treated rats, cell differentiation, including that of spermatogonia, tended to be lower than in controls, maturation levels of

spermatocytes and spermatids were also lower^[17]. In TCDD treated animals, all sperm developmental stages had almost completely returned to the control level, and sperm development was higher than in TCDD treated animals. Significant differences were found in the mean number of RBC and Hb level in Isappukol chooranam treated rats compared to control. But, a significant decrease in levels of blood sugar, serum cholesterol and serum phospholipids in the rats treated with Isappukol chooranam at the both dose levels were observed when compared to control. The result indicates that Isappukol chooranam affects testicle of rats, its increase the weight of this organs, there are significant increase in sperm cells concentration, on the other hand, increased sperm cell count but percentage of motile sperms was observed in only higher dose group animals.

Isappukol chooranam gave significant increase of the testicle mass. The round spermatid, which arises from the second meiotic division, undergoes a series of complex cytological events which transform it into the spermatozoon. This process consists of (i) nuclear condensation and

movement of the nucleus to the periphery of the cell; (ii) formation of a modified lysosome known as the acrosome, which becomes attached to the surface of the nucleus in opposition to the cell membrane; (iii) flagellar formation which includes the development of a core of microtubules, the axoneme, which arises from one of the centrioles of the round spermatid.

In the Isappukol chooranam treated groups, there was a significant excess in the number of primary and secondary spermatocytes and round spermatids. The testis section of normal animals showed clear histological texture. The diameter of seminiferous tubules varied within a range. The tubules having maximum diameter, were not abundant and well within range. Sertoli cells had many cytoplasmic processes which were normal in size. Spermatozoa were embedded in the Sertoli cells and showed normal cytoplasmic granulation. In the spermatogenesis process, the formation of the axoneme, a series of equally spaced doublet microtubules surrounding two single central microtubules, occurs in the cytoplasm adjacent to the Golgi complex, but later in spermiogenesis, this structure becomes lodged at the abacrosomal pole of

the nucleus through a complex articulation forming the neck of the spermatozoon^[18].

Later in the formation of the tail, the axoneme is modified by the development of a series of nine electron dense fibres, termed the outer dense fibres, in the region of the mid-piece of the spermatozoon and distally by the formation of the fibrous

sheath in the region of the principal piece; (iv) finally, following the completion of these events, the spermatid sheds a large part of its cytoplasm as the residual body which is phagocytosed by the Sertoli cell. Leydig cells had normal nuclear size. Luminal part of the tubule were normal in number with bundles of spermatozoa.

Effect of Isappukol Chooranam on body weight of male albino rats.

Parameter	Control	IC 50 mg/kg	IC 100 mg/kg
Initial Body Weight (g)	166.20 ± 1.88	164.20 ± 2.06	168.36 ± 1.86
Final Body Weight (g)	185.80 ± 1.91	188.60 ± 1.33	184.52 ± 2.64

^{ns}P>0.05, values expressed as Mean±SEM, n=6

Effect of Isappukol Chooranam on reproductive organ weights of male albino rats

Organ	Control	IC 50 mg/kg	IC 100 mg/kg
Testes (g)	1.94 ± 0.02	2.20 ± 0.01**	2.33 ± 0.02**
Epididymis (g)	0.33 ± 0.03	0.40 ± 0.01*	0.49 ± 0.01**
Ventral prostate (g)	0.27 ± 0.02	0.34 ± 0.05	0.42 ± 0.01**
Seminal vesicle (g)	0.48 ± 0.03	0.50 ± 0.01	0.60 ± 0.01**
Vas deferens (g)	0.13 ± 0.02	0.14 ± 0.02	0.14 ± 0.01

*P<0.05; **P<0.01, values expressed as Mean±SEM, n=6

Effect of Isappukol Chooranam on hematological and biochemical parameters in male rats after 28days of treatment.

Parameters	Control	IC 50mg/kg	IC 100mg/kg
Hemoglobin (gm %)	12.44± 0.32	12.94±0.13	13.83± 0.22**
RBC (million/cu.mm)	5.57± 0.04	5.72± 0.03*	5.76± 0.03**
WBC (X10 ³ /cu.mm)	4.34± 0.56	4.47±0.36	4.53± 0.82
Blood sugar (mg/dL)	78.03± 1.61	65.34± 2.72	63.33± 5.81*
Blood urea (mg/dL)	31.72± 2.52	31.03±3.15	33.04± 3.03
S.Cholesterol (mg/dL)	83.02± 0.54	69.07± 1.04**	63.03± 4.31**
S. phospholipids (mg/L)	79.04± 0.63	74.08± 0.43**	72.02± 0.53**
S. protein (mg/dL)	7.86± 0.16	8.21±0.64	8.43± 0.39

*P<0.05;**P<0.01, values expressed as Mean±SEM, n=6

Effects of Isabgol Chooranamon sperm count, motility, viability and abnormal morphology after 14 days treatment.

Groups	Count (10 ⁶ /ml)	Motility (%)	Viability (%)	Abnormal Morphology
Control	8.10±0.28	85.40±1.07	96.00±1.52	2.18±0.38
IC 50mg/kg	8.73±0.62	83.10±2.14	95.20±1.77	2.23±0.24
IC 100mg/kg	9.21±0.37*	92.70±1.18**	95.70±1.45	2.17±0.37

**P<0.01, values expressed as Mean±SEM, n=6

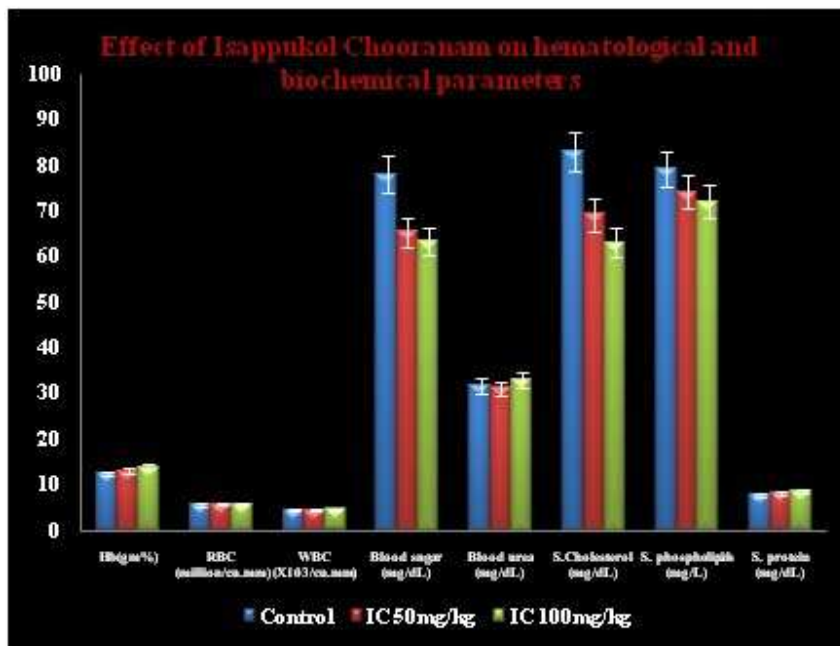
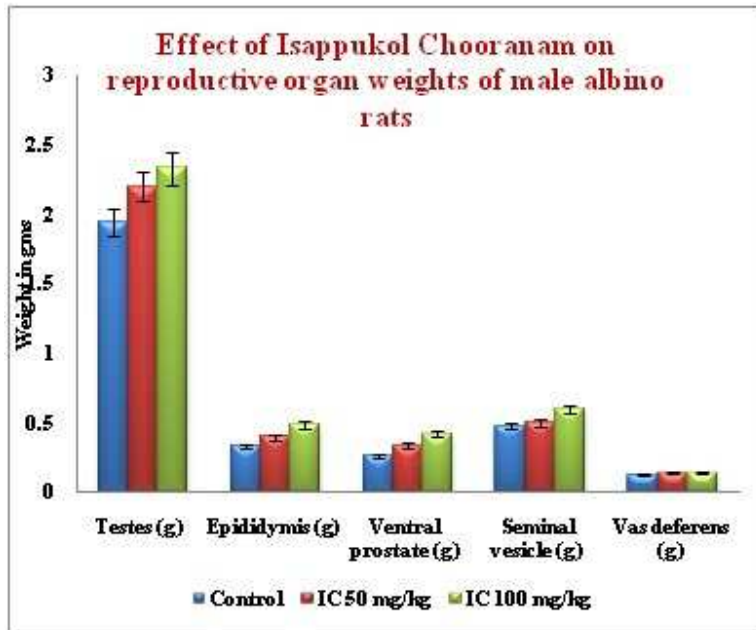
Effects of Isappukol Chooranamom sperm count, motility, viability and abnormal morphology after 28 days treatment

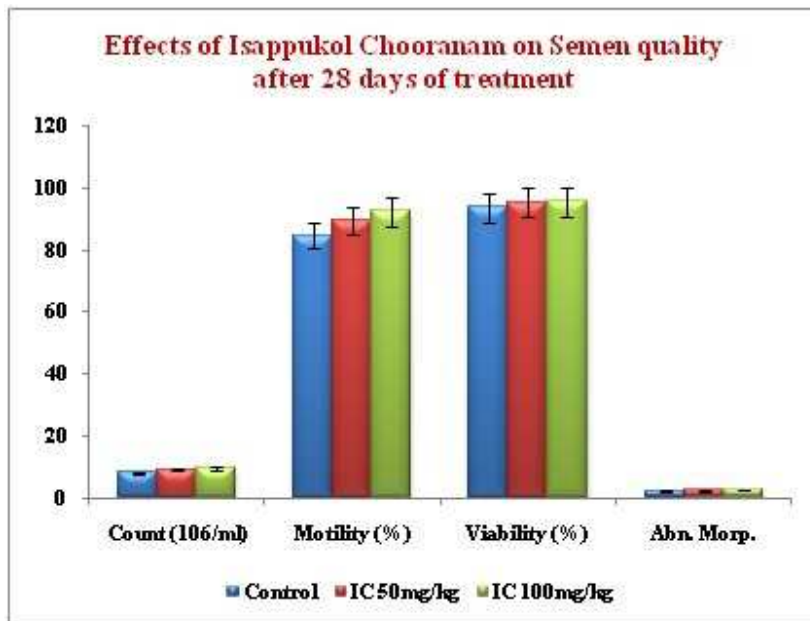
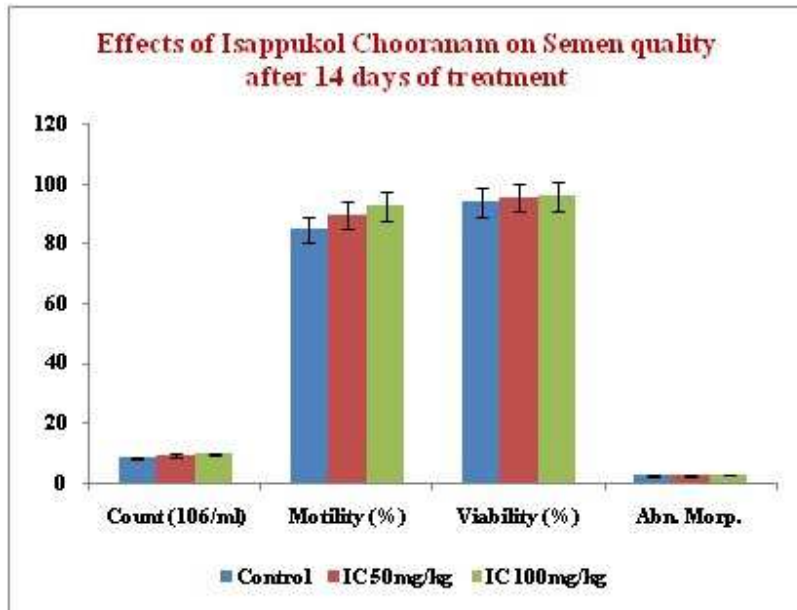
Groups	Count (10 ⁶ /ml)	Motility (%)	Viability (%)	AbnormalMorphology
Control	8.17±0.25	84.60±1.31	93.80±1.91	2.43±0.41
IC 50mg/kg	9.36±0.28*	89.40±2.53	95.37 ±2.21	2.48 ±0.26
IC 100mg/kg	9.53±0.42*	92.50±1.84*	95.62 ±1.87	2.72 ±0.28

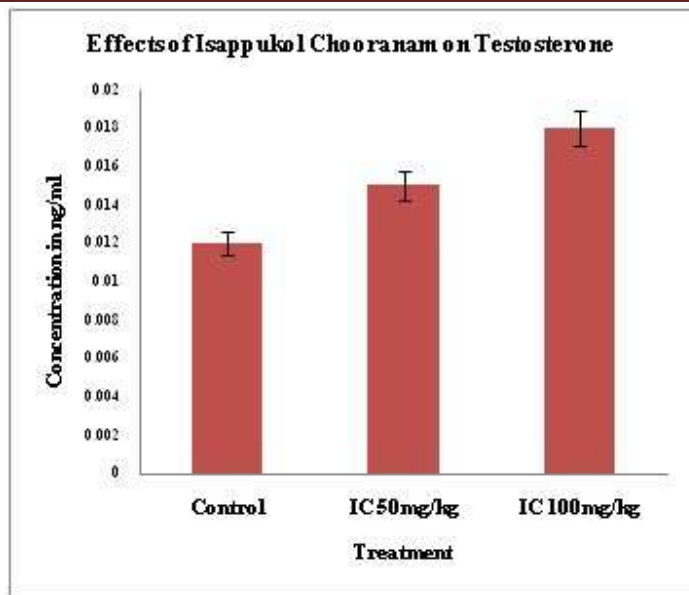
*P<0.05, values expressed as Mean±SEM, n=6

Effects of Isappukol Chooranamom Testosterone level after 28 days treatment

Groups	Testosterone level (ng/ml)
Control	0.012±0.018
IC 50mg/kg	0.015±0.014**
IC 100mg/kg	0.018±0.017**







CONCLUSION

The results obtained in the present study strongly confirms the positive beneficial effects on male reproductive system by Increased number of spermatozoa in seminiferous tubules and which is evident by increase in Spermatogenic elements as compared to control.

REFERENCES

1. Martin, Mary C. "Infertility." In current Obstetric and Gynecologic Diagnosis and Treatment, edited by Alan H. Cecherney and Martin L. Pernoll. Norwalk, CT: 1994.
2. Smith, J. F., Walsh, T.J., Shindel, M., Paul, J., Turek, P. J., Wing, H., Pasch, L. and Katz, P. P. (2009): Sexual, Marital, and Social Impact of a Man's Perceived Infertility Diagnosis. J. Sex Med., 6(9): pp. 2505–2515.
3. Brugh, V.M. and L.I. Lipshultz, 2004. Male factor infertility: Evaluation and management. Med. Clin. North Am, 88: 367-385.
4. Muhammad Hafeez, Afzal Ahmed, Khan Usmanghani, E. Mohiuddin, H.M. Asif, Muhammad Akram¹ and Riazur Rehman, Clinical Evaluation of Herbal Medicine for Oligospermia. Pakistan journal of Nutrition 10(3):238-240, 2011.
5. Kmietowicz, Zosia."Infertility; Treatment." NWHRC Health Center March 10, 2004,"Smoking is Causing Impotence,

Miscarriages, and Infertility", British Medical Journal February 14, 2004: 364.

6. Rahul B. Patil, Shreya R. Vora and Meena M. Pillai. Protective effect of Spermatogenic activity of Withania somnifera(Ashwagandha) in galactose stressed mice, Annals of Biological Research, 2012, 3 (8):4159-4165, (<http://scholarsresearchlibrary.com/archive.html>).

7. Anonymous.Koshayi Anuboga Vaithya Brama Ragasiyam- part II, pp: 108,(1999), Thamarai noolagam,vadapalani, Chennai.

8. Venugopal. Magalir Maruthuvam, pp.96 (2008): Dept of Indian Medicine and Homeopathy, Chennai, Govt of Tamilnadu.

9. Murugesu mudhaliyar, Gunapadam mooligai vaguppu, (part-1), pp.72-435, Dept of Indian Medicine and Homeopathy, Chennai:Govt of Tamilnadu.

10. Anonymous.Koshayi Anuboga Vaithya Brama Ragasiyam- part II, pp.108,(1999), Thamarai noolagam, vadapalani, Chennai.

11. OECD guideline for testing of chemicals. <http://www.oecd.org/chemicalsafety/risk-assessment/1948241.pdf>.

12. Johnson, L., Dickerson, R., Safe, S.H., Nyberg, C.L., Lewis, R.P., and Welsh, T.H., Reduced Leading cell volume and function in adult rats exposed to 2,3,7,8-tetrachlorodibenzo-p-dioxin without a significant effect on spermatogenesis. Toxicology 76, 103-118 (1992).

13. Morakinyo A. O, Adeniyi O.S and Arikawe A.P, Effects of Zingiber Officinale on Reproductive Functions in the Male Rat, Journal of Medicine and Medical Science Vol. 3(11) pp. 692-696, November 2012,

14. M. A. Awal, M. N. H. Siddiqi , M. Kurohmaru , B. B. Andriana , T. Mizukami , Y. Kanai and Y. Hayashi, Biochemical Effects of 2, 3, 7, 8-tetrachlorodibenzo-p-dioxin (TCDD) on the Sertoli Cell Culture from Prepubertal Male Wistar Rats,Journal of Medical Sciences, 1: 311-315.

15. P. O. Ajah and M. U. Eteng, Phytochemical screening and histopathological effects of single acute dose administration of Artemisia annual. On testes and ovaries of Wistar rats, African Journal of Biochemistry Research Vol. 4(7), pp. 179-185, July

2010.<http://www.academicjournals.org/AJB>

R.

16. D. M. deKretser , K. L. Loveland, A. Meinhardt, D. Simorangkir and N. Wreford, Spermatogenesis

(<http://humrep.oxfordjournals.org>).

17. M. A. Awal, M. N. H. Siddiqi , M. Kurohmaru , B. B. Andriana , T. Mizukami , Y. Kanai and Y. Hayashi, Biochemical Effects of 2, 3, 7, 8-tetrachlorodibenzo-p-dioxin (TCDD) on the Sertoli Cell Culture from Prepubertal Male Wistar Rats, Journal of Medical Sciences, 1: 311-315.

18. Da Christoph Petersen , Laszlo Füzesi and Sigrid Hoyer-Fender¹, Outer dense fibre proteins from human sperm tail: molecular cloning and expression analyses of two c DNA transcripts encoding proteins of ~70 k ,Molecular Human Reproduction Mol. Hum. Reprod. (1999) 5 (7): 627-635. doi: 10.1093/molehr/5.7.627 .