



EVALUATION OF SAFETY AND THERAPEUTIC EFFICACY OF SIDDHA FORMULATION PANCHAMUGA CHENDURAM (INTERNAL MEDICINE) AND POOVARASAM PATTAI ENNAI (EXTERNAL MEDICINE) ON VITILIGO PATIENTS (VENPADAI)

Muralidass S D^{1*}, Ramaswamy R S², Muthukumar N J³, Mahalakshmi V⁴, Mahadevan M V⁵, Periyasami D⁶

1* Medical Officer, Siddha Central Research Institute, Chennai

2 Director General, Central Council for Research in Siddha, Chennai

3 Associate Professor, Dept of Sirappu Maruthuvam, National Institute of Siddha, Chennai

4, 5, 6 Lecturers, Dept of Sirappu Maruthuvam, National Institute of Siddha, Chennai

ABSTRACT

An open clinical trial of *Panchamuga Chenduram* (Internal medicine) and *Poovarasam Pattai Ennai* (External medicine) for *Venpadai* (Vitiligo - hypopigmented patches of irregular shape in the epidermis of skin) patients. Patients were diagnosed clinically and admitted for the trial. The above study was get approval from Institutional Ethical Committee (IEC) of National Institute of Siddha (NIS). The evaluation the therapeutic efficacy of the above drugs were carried out in the patients of *Venpadai* (Vitiligo) and assessment were analysed and the results are presented. There was a significant improvement in production of repigmentation and reduction of the size of the hypopigmented patches.

Keywords: *Venpadai, Panchamuga Chenduram, Poovarasam Pattai Ennai, NIS, Siddha*

Corresponding Author: Dr. S. D. Muralidass,

Email id: drmuralinis@gmail.com

INTRODUCTION

Siddha system is an integral part of socio-cultural milieu of Tamil Nadu. The history of Siddha medicine is as old as the history of the Tamil culture and civilization.¹ The contribution of Siddhars to Siddha literature with its boundless therapeutics and wonderful pharmaceutical medicine preparations is acclaimed par excellence even in this 20th century owing to remarkable results.² In Siddha system of medicine, Vitiligo is described as *Venpadai*. Vitiligo is an acquired idiopathic depigmentary condition, which though worldwide in distribution, is

most common in India, Egypt and other tropical countries.³ Vitiligo affects approximately 1-4 % of the world population⁴. Adults and children of both sexes are equally affected although the greater number of reports among females is probably due to the greater social consequences to women and girls affected by this condition.⁵

Scientifically validated and technologically standardized AYUSH products may be explored on a fast track using innovative approaches like reverse pharmacology and systems biology, which are based on traditional medicine knowledge.⁶

MATERIALS AND METHODS

This open clinical trial was carried out with the approval from Institutional Ethical Committee (IEC) of NIS (Ethical Committee Clearance Certificate No - F.No.NIS/6-20/Res/IEC/10-11 Dated on 29.11.2010). The required drugs for preparation of trial medicines were purchased from a well reputed country shop and were authenticated by the faculty members of Department of Gunapadam and Department of Medicinal botany of NIS. The trial medicines were prepared in the Gunapadam Laboratory of NIS as per Sastric methods. After getting the proper approval from IAEC of NIS (Institutional Animal Ethical Committee Certificate no - NIS/3-1/2011-12) the Acute Toxicity Study of internal drug *Panchamuga Chenduram* was done at Animal House, NIS. Bio-chemical analysis and Physio-chemical analysis of internal drug *Panchamuga Chenduram* were also done at Sophisticated Analytical Instrument Facility, IITM, Chennai-36.

This study was conducted in 40 patients in the Department of Sirappu Maruthuvam, Ayothidoss Pandithar Hospital, National Institute of Siddha (NIS), Tambaram Sanatorium, Chennai-47. The following trial medicines were given for 48 days (One Mandalam). The Internal Medicine; *Panchamuga Chenduram* was given to patient in a dose of 100 mg twice a day with Honey as adjuvant⁷ and the external medicine; *Poovarasam Pattai Ennai* was also applied daily in the affected parts twice a day for a period of 48 days⁸. Purgation with *Viresana Boopathy Tablet - 2 No* early morning with hot water was given for balancing the deranged Mukkutram a day before treatment. Laboratory investigations were done on 0th day, 24th day and 49th day of the trial. Photographs of lesions were taken before, during and after the trail.

ACUTE TOXICITY STUDY (WHO GUIDELINES, 1993)


The animals were monitored for behavioral parameters like 1. Awareness (Alertness, Visual placing, Stereotype, Passivity) 2. Mood (Grooming, Restlessness, Irritability, Fearfulness) 3. Motor activity (Spontaneous activity, Reactivity, Touch response, Pain response). For the first four hours after doing administration, body weights of the animal were monitored at weekly interval. The animals were monitored for apparent signs of toxicity for 14 days. The animals that die within this period will be subjected to necropsy. All animals were weighed and sacrificed on the 15th day after administration and then the vital organs including heart, lungs, livers, kidneys, sex organs and brain were grossly examined. In the acute toxicity in animal models reveals no abnormality hence the drug is found safe.

S. No	Group	No of mice
1	Vehicle control (Saline)	10 (5 male, 5 female)
2	Toxic dose (10X therapeutic dose-36mg) (Single dose-(0.36mg))	10 (5 male, 5 female)

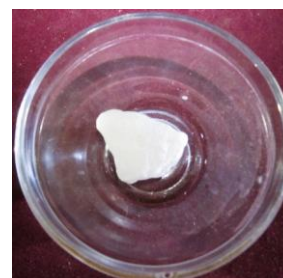
INGREDIENTS OF INTERNAL MEDICINE (PANCHAMUGA CHENDURAM)



RASAM



NELLIKAI GANTHAGAM



VEERAM



THALAGAM



KAATTAMANAKKU



PANCHAMUGA CHENDURAM

INGREDIENTS OF EXTERNAL MEDICINE (POOVARASAM PATTAI ENNAI)



POOVARASAM PATTAI



GINGELLY OIL



POOVARASAM PATTAI ENNAI

DISCUSSION

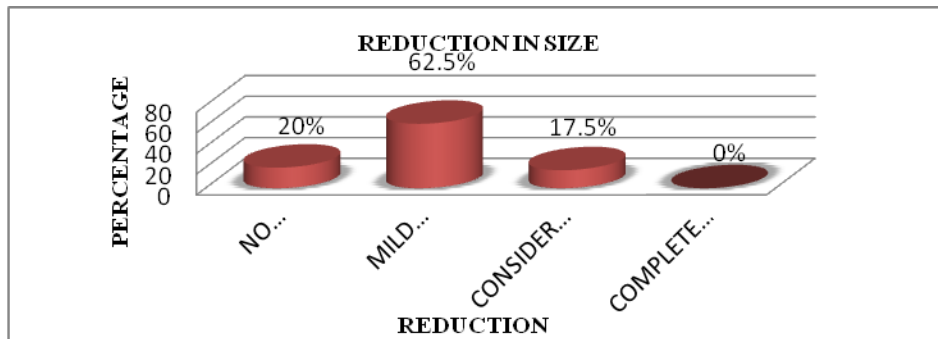
Among the several cases of Vitiligo reported in NIS hospital, 40 patients were studied through Vitiligo Clinical Assessment Scale and the results are presented. In this study it was found that the trial drugs *Panchamuga Chenduram* and *Poovarasam Pattai Ennai* are effective in producing repigmentation and reducing the size of the hypo pigmented patches in the treatment of Vitiligo (*Venpadai*).

1. Vitiligo Clinical Assessment Scale⁹

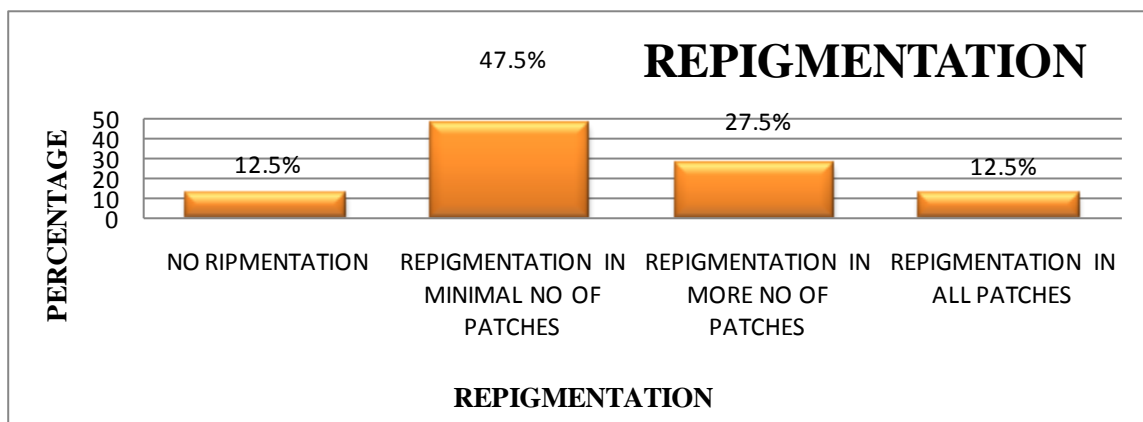
Parameter	-	+	++	+++	++++
Change in color	No change	Yellowish tint	Slight contrast between lesion color and surrounding skin color	No contrast between lesion color and surrounding skin color	100% remission in all treated lesions
Change in size	No change	Up to 5 mm reduction in diameter	Up to 10 mm reduction in diameter	More than 10 mm reduction in diameter	
Folliculocentric repigmentation	No repigmentation	Up to 5 mm perifollicular repigmentation	Up to 10 mm perifollicular repigmentation	More than 10 mm perifollicular repigmentation	

-, No response; +, mild response; ++, moderate response; +++, marked response; +++++, complete response.⁹

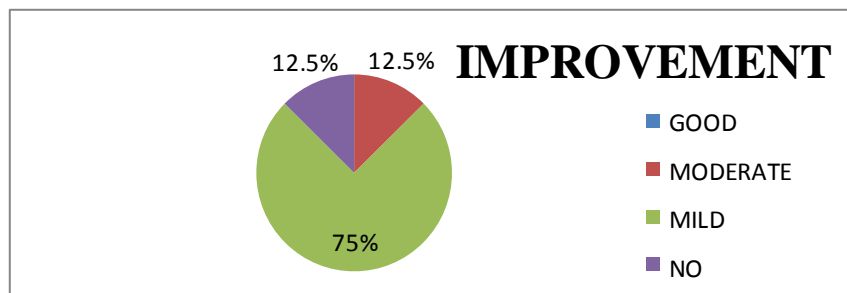
2. Reduction in Size after Treatment



3. Repigmentation Pattern after Treatment



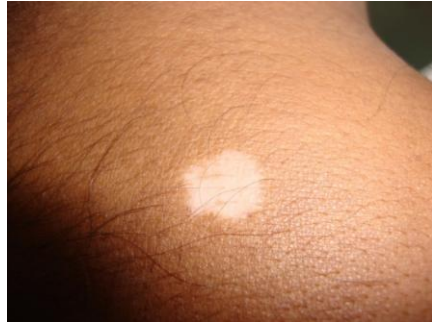4. Results after Treatment



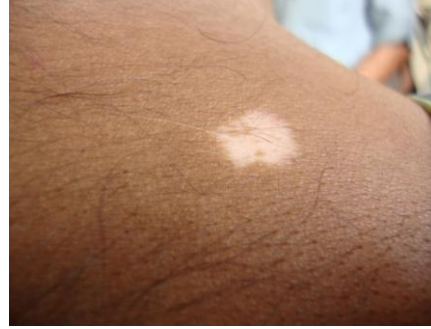4. Photographs showing the Vitiligo patch of left upper scapular region at entry, during and after treatment. (Patient's OP No: B 17944 Age: 41 Sex: Male)

Before Treatment 1st Visit (27.07.11)

2nd Visit (08.08.11)

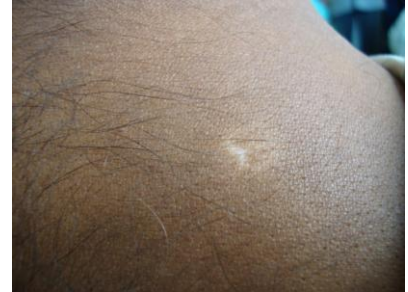
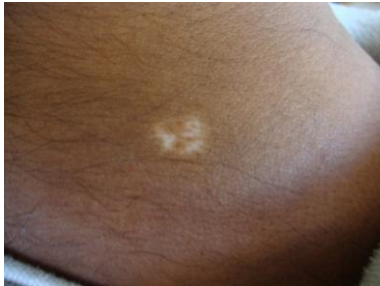
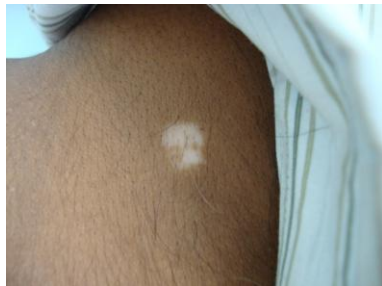3rd Visit (21.08.11)



4th visit (04.09.11)

After Treatment 5th visit (17.09.11)



RESULTS

The clinical study reveals that the trial drug showed Grade 2 – moderate improvement in 12.5% of the cases, Grade 3 – mild improvement in 75% of the cases, Grade 4 – no improvement in 22.5% cases. Clinically, no adverse effects were reported during the trial and the laboratory investigations were also within normal limits. So, the drug is assumed to be safe for humans. Acute toxicity study in animal models reveals that the internal drug “Panchamuga Chenduram” is safe. The safety of the trial drug was proved from this study. It was also observed during this trial that no new lesions were formed and there was no increase in any existing lesion was found in all the 40 patients.

CONCLUSION

This clinical study results showed significant reduction in the size of the hypopigmented patches and the production of repigmentation in the Vitiligo patches and suggesting that daily long term administration of the drug could be safe. No complications were observed during the course of the study. All the patients responded to the drug well and were very comfortable and no new lesions were formed and there was no increase in any existing lesion was found in all the 40 patients. Because of the encouraging clinical results, it could be concluded that the trial

medicines are effective in producing repigmentation and reducing the size of the hypopigmented patches in the treatment of Vitiligo

ACKNOWLEDGMENT

I express my profound sense of gratitude to **Prof.Dr.K.Manickavasakam**, Director, NIS, Chennai for his valuable guidance and encouragement in this study. I express my sincere thanks to **Chairman and Members** of Institutional Ethical Committee (**IEC**) and Institutional Animal Ethical Committee (**IAEC**) of NIS, **Dr.P.Aravind**, Asst.Prof, (Medicinal Botany) and **Faculties of Department of Gunapadam**, NIS, **Dr.V.Suba**, Asst.Prof, (Pharmacology), NIS, **Prof.Dr.R.Murugesan**, Scientific Officer, Sophisticated Analytical Instrument Facility, Indian Institute of Technology, Chennai for their guidance and co-operation. I express my special thanks to **Prof.Dr.V.Arunachalam**, Principal, Santhigiri Siddha Medical College, Trivandrum who constantly encouraging me for presenting papers in various scientific conferences. Last but not the least, I acknowledge the patients for their consent to take part in this study and to make co-operation in continuing the treatment.

REFERENCES

1. *The siddha pharmacopoeia of India Part – I, Volume – I, First edition, Government of India*
 2. <http://www.siddhamedicine.com/uniqueness.html>,6.36 [ISD].
 3. Behl P. N. *Practice of Dermatology 7th ed 1990, CBS Publishers & Distributors; pp. 317-323*
 4. Ortonne Jan - Paul and Bose Sumit Kumar. *Vitiligo: Where Do We Stand; Pigment Cell Research 1993; 6:61-72.*
 5. Forschner T, Buchholtz S, Stockfleth E. *Current State of Vitiligo therapy- Evidence Based Analysis of the Literature, JDDG 2006; pp- 467-476.*
 6. *Reverse Pharmacology and Systems Approaches for Drug Discovery and Development, Current Bioactive Compounds 2008, Vol. 4, No. 4 Patwardhan et al*
 7. *Pulippaani Munivar Vaithiyam 500 (Page no 61)*
 8. *Gunapadam Mooligai Vaguppu (Page no 706)*
 9. *JEADV (Journal of the European Academy of Dermatology and Venereology)*
-